

The importance of radiological investigations in craniocerebral trauma

Michał Mateusz Piotrowski, MSD 2 year

Supervisor: prof. dr hab. n. med. Dariusz J. Jaskólski, Assistant Supervisor: dr.n.med Ernest Bobeff
Klinika Neurochirurgii i Onkologii Układu Nerwowego USK nr 1 im. Norberta Barlickiego w Łodzi

TBI accounts for **40%**
of all injury-related deaths

Materials & Methods

The retrospective study was conducted at the Department of Neurosurgery and Neurooncology of No. 1 in Lodz, Poland. The study was conducted based on ethical principles. Exclusion criteria included: patient treated conservatively and patient operated on due to post-traumatic lesions other than acute subdural hematoma. A group of randomly selected patients operated due to acute subdural hematoma between 2015 and 2022 year were included in the study. All patients had pre- and post-operative CT scans.

Patients after TBI year 2015-2022 = **1917**

EXCLUSION CRITERIA

Conservative treatment = 783

Had elective surgery due to a chronic SDH = 418

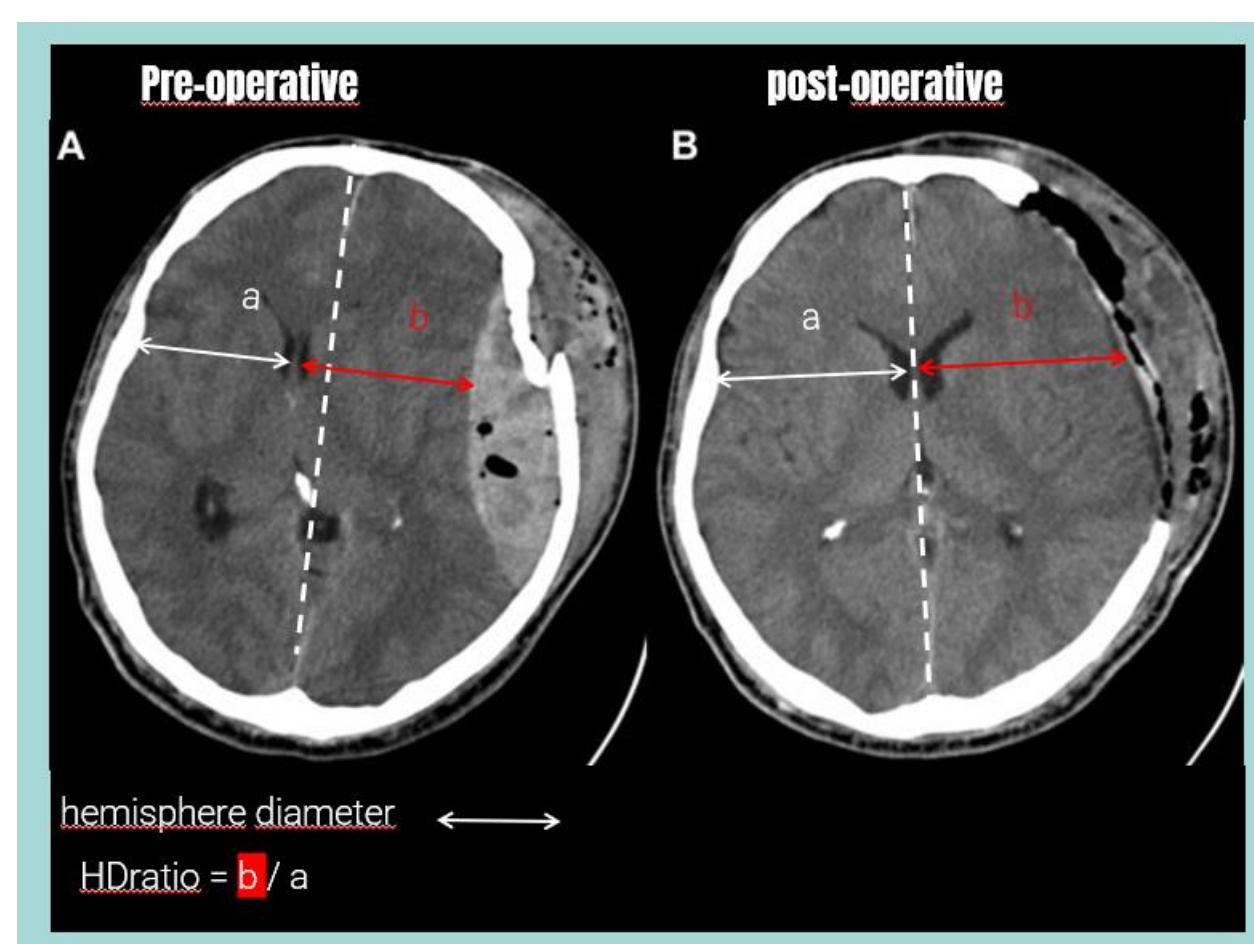
Had elective surgery due to a ICH = 202

Had elective surgery due to a EDH = 96

Patients who received surgical intervention for an acute SDH = **418**

Clinical data were collected including age, gender, length of hospitalization, preoperative consciousness assessed by GCS, presence of anisocoria, limb paresis, as well as the need for mechanical ventilation and any previous surgery. Preoperative head CT was evaluated noting the presence of intracranial pathology in the form of acute subdural hematoma (SDH), intracerebral hematoma (ICH), intraventricular hematoma (IVH), and post-traumatic subarachnoid hemorrhage (tSAH). HDratio values, the degree of midline shift (MLS), and the degree of compression of the basal vessels of the brain were calculated from preoperative and postoperative head CT.

Hemispheric Diameter & HDratio



Treatment outcome was assessed according to the Glasgow Outcome Scale (GOS). The endpoint of the study was death or vegetative state of the patient (GOS 1-2), which signified poor treatment outcome. Statistical analysis was performed using Statistica 13 (StatSoft, Oklahoma, US). Continuous and ordinal variables were compared using the Mann-Whitney U test. Categorical variables were compared using Fisher's two-sided test.

Objectives

- To evaluate the prognostic value of the hemispheric diameter ratio (HDratio) among patients treated surgically after severe traumatic brain injury (TBI).
- To evaluate the diagnostic value of the hemispheric diameter ratio (HDratio) in patients eligible for surgical treatment after TBI.

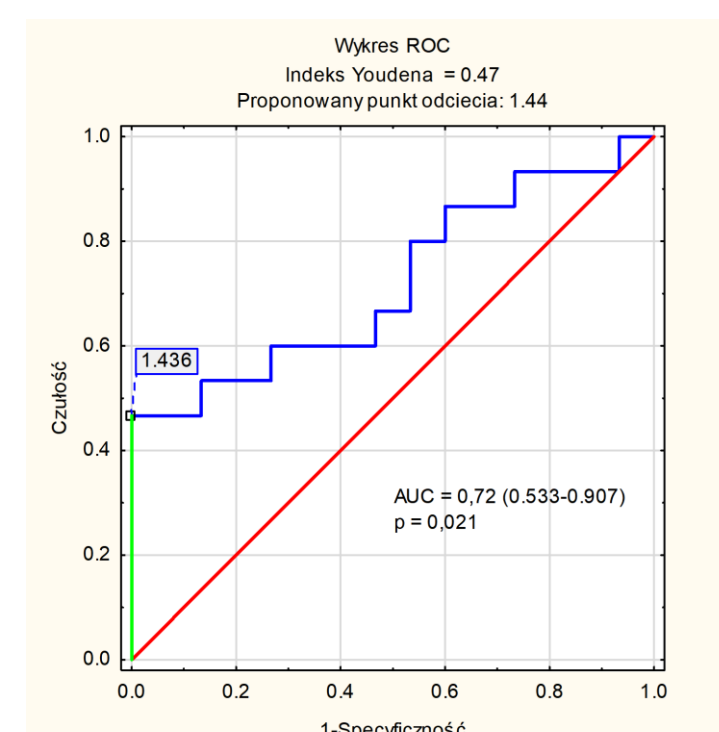
Men are twice as likely to suffer from craniocerebral injuries

Validation of Hypotheses

- The hemispheric diameter ratio assessed using a postoperative CT scan from patients with traumatic brain injury has prognostic significance.
- The hemispheric diameter ratio assessed using a preoperative CT scan has diagnostic significance and can be used to qualify patients for craniectomy after severe traumatic brain injury.

Results

Of the 418 patients operated on for acute SDH, the data of 52 randomly selected patients (12 women and 40 men) were analyzed. Thirty-seven patients underwent DC, while the remaining 15 patients underwent craniotomy, i.e., the bone flap was restored after removal of the hematoma. The median age was 62 years (IQR 50-74). The median GCS on admission was 9 (IQR 4-11). Poor treatment outcome was associated with lower GCS score on admission ($p < 0.001$) (GOS 1-2 89% vs. 33%, $p < 0.001$) and respiratory failure on admission (GOS 1-2 94% vs. 34%, $p < 0.001$). All patients with tightened basal vessels had a poor outcome (100% vs. 40%, $p = 0.042$). Patients with lower HD on the first head CT scan had a better prognosis (Figure 2., $p = 0.041$). The ROC curve shown in Figure 3. depicts the effectiveness of the HD index in predicting poor outcome. Based on the Youden index, the best cutoff point was determined. Poor treatment outcome was observed in all patients who had an HD index greater than or equal to 1.436 in the first study (Figure 3.).



The ROC curve shown in Figure 3

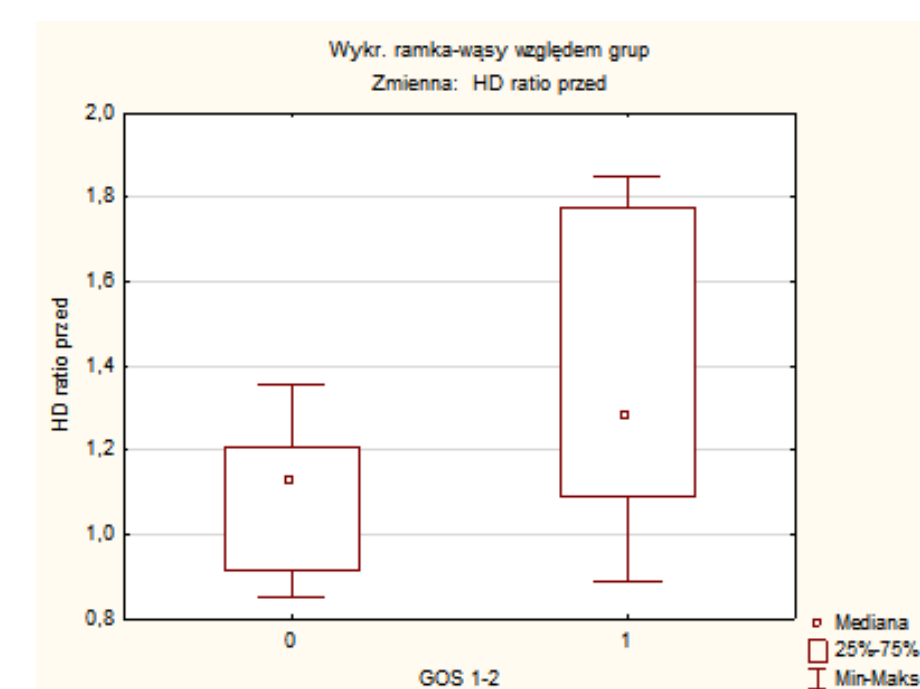


Figure 2 test U Mann-Whitney, $p = 0.041$

Discussion

The analysis presented here is a preliminary study of randomly selected patients from the target group. Sauvigny et al (2016) conducted a study on 40 post-TBI patients operated on for acute subdural hematoma and observed that postoperative HD has prognostic significance. In our analysis, we found no such relationship. This may be related to other exclusion criteria. Our analysis, included patients who had newly diagnosed lesions on postoperative head CT: post-traumatic ICH, and post-traumatic tSAH. In addition, we did not exclude patients who died before transfer to the ICU, which was the case in the study I mentioned. At this stage of the study, our second research hypothesis cannot be confirmed, as the initial analysis included only 15 patients who underwent craniotomy, and among them, only three required reoperation and removal of the bone flap.